

Wobblers - Diagnostic Approach Within and Outside the Americas

Joe Mayhew
Massey University
NEW ZEALAND

i.g.mayhew@massey.ac.nz

Abstract

A wobbler is an ataxic horse, no more, no less. Thus, interpretation of precise neurologic examination findings along with results of ancillary test results – having due respect for accuracy and inaccuracy parameters of these – are relied upon to determine a primary clinical diagnosis and its associated credibility or likelihood of being correct. In general the more objective our test parameters are and the more cautious our probability estimates are, the more repeatable and reliable our diagnoses and prognoses are. This talk aims to put various clinical, laboratory and imaging test results in perspective with respect to evaluating wobblers in practice.

Introduction

Lesions resulting in tetraparesis, paraparesis and ataxia of the limbs occur in the spinal cord, spinal nerve roots and ganglia, and neural plexuses and nerves of the limbs. If following the neurologic evaluation, cerebellar involvement can be ruled out in a particular wobbler case showing ataxia of the limbs then the clinician must attempt to differentiate between the remaining disorders producing degrees of tetraparesis, paraparesis, and episodic weakness to arrive at a diagnosis. With brain stem diseases there usually are signs such as somnolence and cranial nerve functional abnormalities. Patients having signs consistent with diffuse weakness due to lower motor neuron and neuromuscular diseases, either static, episodic or exercise-associated, may also have evidence of cranial nerve dysfunction but should remain reasonably bright and alert and not demonstrate ataxia. However, with profound weakness, it can be very difficult to determine the presence or not of ataxia, particularly if the patient is reluctant to move.

Spinal cord disease is common. A horse showing variations of ataxia and weakness is called a wobbler and this should be used as a generic term, not defining the cause of the syndrome. However, some people equate the term wobbler with the disease cervical vertebral malformation and malarticulation [CVM].

Once the clinician has defined the presence of ataxia due to spinal cord disease as opposed to peripheral nerve, brainstem or cerebellar syndromes, use of ancillary aids can be useful to distinguish some of the common causes. Many cases of wobblers suffering spinal trauma and those with vertebral malformations such as congenital occipitoatlantoaxial defects in particular breeds are generally well defined with plane lateral radiographs. Spinal cord anomalies on the other hand may or may not be associated with vertebral changes evident with radiographic examinations. Confirmation of specific toxic myelopathies in vivo are often problematic and circumstantial evidence is often all that is available for clinical diagnosis of ataxia due to toxicosis associated with stinging nettle, ear mites, ivermectin, monensin, fluphenazine, swainsonine, vetch and sodium bromide¹⁻⁶.

Numerous inflammatory and vascular processes result in spinal ataxia without apparent regard for region of the world. These include bacterial osteomyelitis, verminous myelitis, fibrocartilage embolic myelopathy and granulomatous myelitis. Several of these diseases and syndromes are discussed in the paper on Emerging Syndromes and in the literature^{1-5, 7-13}.

It behooves the equine clinician to complete a thorough neurologic workup as early as possible in the course of all neurologic syndromes. This is particularly so as more is known about various spinal cord diseases and more advanced medical and surgical therapeutic regimens become available. Ancillary aids, such as neuroradiology, advanced computerized imaging techniques, electrodiagnostic testing and spinal fluid analysis can be of tremendous help in developing a plan for treatment early in the course of disease, before permanent neurologic signs and the consequent hopeless outlook for return of function arise. A CSF sample is best taken at the lumbosacral space from patients with this syndrome because the fluid sampled is likely to be closest to the lesion.

The remainder of this paper will attempt to put in perspective the clinical utility of diagnostic aids for diseases that commonly produce spinal ataxia in horses both internationally and regionally. Emphasis is on various forms of myelitis and in particular on cervical vertebral malformation and malarticulation [CVM].

West Nile Virus [WNV] Encephalomyelitis

About 85% of cases of WNV encephalomyelitis in North America are ataxic, almost one-half of the cases are weak and many of these are recumbent or have difficulty rising or both, close to 40% have generalized muscle fasciculations, less than one-quarter are febrile and less than one-fifth of the cases have a paralyzed or droopy lip, and 5-10% have a twitching face or muzzle, teeth grinding or blindness¹⁴⁻¹⁸. When profound weakness and tremors are identified in concert with hyperesthesia and ascending paralysis rabies, botulism and EHV1 myeloencephalopathy should also be considered along with other encephalitides such as WEE, EEE and VEE.

Analysis of CSF reveals abnormalities in most [c75%] samples, especially those from the lumbosacral cistern [c90%], with a monocytic pleocytosis and elevated protein content predominating.

Several diagnostic tests for the presence of antibody and antigen of WNV in serum and CSF are available in different laboratories and others will become available and popular in the future^{14, 16, 19, 20}. An IgM capture enzyme-linked immunosorbent assay, microtiter virus neutralization test and a plaque neutralization test have given quite accurate indications of WNV infection^{21, 22}.

As WNV has spread to North and South America in the last decade and climatic patterns continue to change, and particularly as the vectors for WNV are apparently present in many other countries such as those in the UK and Australasia, vets must be on the lookout for such cases in horses that may accompany unexpected death of susceptible birds such as crows.

Togaviruses

The important diseases associated with this viral complex are the American EEE, WEE and VEE encephalomyelitides. Getah virus probably is widespread in Japan, SE Asia and Australasia but rarely is associated with self-limiting disease in horses and does not appear to produce signs of encephalitis²³.

Rising acute and convalescent serum hemagglutination-inhibition titers or a high terminal titer for a specific strain can be helpful in coming to a clinical diagnosis. The use of IgM specific enzyme immunoassays may help in the ante mortem diagnosis of EEE²⁴. The use of RT-PCR viral antigen sequence amplification from serum samples may well be an accurate, and certainly rapid, means of positively identifying the infective viruses²⁵. Analysis of CSF shows leukocytosis, often initially neutrophilic, especially with EEE, as well as increased protein content and xanthochromia. Occasionally, a prominent CSF eosinophilic pleocytosis is detected with EEE. The CSF changes are less prominent with WEE, and probably with VEE also.

Viral isolation from brain tissue usually is possible but it is difficult to isolate the virus from cerebrospinal fluid. Standard immunohistochemical assays²⁶ and detection of viral RNA sequences using in situ hybridization²⁷ and particularly other nucleic acid sequence amplification methods²⁸ are very reliable at accurately diagnosing these diseases on formalin fixed CNS tissue.

Currently waves of Togaviral encephalomyelitis in horses occur in conjunction with reasonably predictable, national and international bird migrations on a semi-seasonal basis. As migration patterns may alter then vigilance for these diseases must be maintained in countries at the periphery of such migratory paths.

Other Encephalitic Viruses of Equids

Another Flavivirus²⁹, Japanese encephalitis virus, tends to result in mild generalized illness in horses throughout Asia and has resulted in progressive neurologic signs in horses in Japan and Taiwan including hyperesthesia, apprehension and manic behavior due to lymphocytic encephalitis³⁰⁻³³. Rabies has to be a

major differential diagnosis. Several other Flaviviruses have been studied but they do not appear to be important in causing encephalitis in large animals³⁴⁻³⁶.

Hendra virus, a paramyxovirus, has resulted in acute disease and death in horses and humans in Australia³⁷. Neurologic signs were reported in 2 horses³⁸ although further isolated individual and clusters of cases have occurred within the areas inhabited by *Pteropus sp.* fruit bats in which the virus is endemic³⁹. The role of Snowshoe Hare virus⁴⁰, Main Drain virus⁴¹ and Powassan virus⁴² in the clinical syndrome of viral-type encephalomyelitis in horses is unclear.

Borna Disease Virus Encephalomyelitis

A modest lymphocytic pleocytosis often is seen in CSF during the early stages of the disease. Testing for the presence of serum and CSF antibodies can add to confidence in a clinical diagnosis in acute disease but antibody tends not to be present in mild, chronic cases^{43,44}.

Although most clinically affected patients will produce circulating antibodies, they can develop late or never. The encephalomyelitis is regarded as representing a cell mediated immune response to the virus involving CD4+ and CD8+ cells. Virus isolation and in situ RT-PCR techniques are required to confirm the disease⁴³⁻⁴⁵.

Controversy still occurs over definitive diagnostic criteria for Borna disease^{46,47}. The high seroprevalence of the disease in horses in Europe and the presence of many unusual and ill-defined neurologic syndromes in this species, invite irrational clinical diagnoses of Borna disease being entertained⁴³, as may tend to occur with equine protozoal myeloencephalitis due to *Sarcosystis neurona* in the Americas.

Equine Herpes Virus-1 [EHV-1] Myeloencephalopathy

Cerebrospinal fluid, especially from the LS space, may have xanthochromia and elevated protein content [0.01-0.04 g/L] reflecting the leakage of blood pigments from vasculitis, but it has few cells^{48,49}. Pre-existing EHV-1 serum-neutralization titers do not appear to be protective and may in fact be necessary for the disease to occur. A fourfold rise in an EHV-1 serum titer from acute to convalescent samples is good circumstantial evidence of EHV-1 infection in individuals or in associative herd animals. Viral isolation from nasal swab, tracheal wash fluid and blood buffy coat cultures is also good evidence for the disease^{48,50,51}.

Tentative clinical diagnosis can be made based on clinical signs, previous or current febrile upper respiratory tract disease or abortions in co-habiting horses, and the presence of xanthochromic, hypocellular cerebrospinal fluid. Diagnostically, if an EHV virus can be isolated from pharyngeal or nasal secretions this strongly suggests that this particular virus strain is the cause of the neurological disease. PCR testing can be used to look for viral DNA shedding in pharyngeal or nasal secretions, and its presence in peripheral blood buffy coat indicating current or recent viremia. In comparison, vaccine strains likely are not consistently present in buffy coat and pharynx post vaccination⁵². A significant rise in anti-EHV-1 viral neutralization, complement fixation or ELISA antibody titers between acute and convalescent samples indicates recent virus infection³⁵.

Outbreaks of paralytic EHV-1 infection have been occurring with some regularity within NA. EHV-1 is present in countries such as New Zealand where the paralytic form has not yet been recognized. It thus behooves us to be aware of the possibility of introduction of paralytic strains of the virus into such countries in the future.

Equine Protozoal Myeloencephalitis [EPM]

Currently, *Sarcocystis neurona*, the major cause of EPM appears to be confined to countries of North, Central and South America. The disease can thus occur in horses that have spent some time in any of those countries. Outwith those areas cases of EPM have been confirmed or strongly suspected to occur in horses that left such countries up to many months previous to prominent myeloencephalitis occurring.

A single, highly accurate, premortem diagnostic test for EPM does not currently exist⁵³. A comparison of characteristics of several tests used to assist in diagnosis of EPM is given in Table 1 [Rob

MacKay, *pers. comm.*]. The *S. neurona* western blot [WB] assay detects the presence of *S. neurona* specific antibodies in serum or CSF. The presence of antibodies in the serum only indicates exposure but the presence of *S. neurona* specific antibodies in CSF is more suggestive but not diagnostic for the presence of active infection. Antibodies can be present in the CSF in active disease however false positive results have been widely reported, especially with contamination of CSF by serum. Sensitivity and specificity for the disease by immunoblot testing of CSF have been estimated at around 70-90% depending on sampling methodology. Furthermore, the positive predictive value [PPV] using CSF immunoblot testing for the presence of EPM in horses with clinical neurologic disease probably is around 85% and the negative predictive value [NPV] for EPM probably 92%. This also means that testing any horse in [or from] an indigenous area, with or without clinical neurologic signs, will be constrained by a PPV of say 10% and a NPV of say 99%, given the rate of occurrence of the disease as ~1%. A corollary of this is that normal horses should probably not be tested. If however a positive CSF immunoblot test result is forthcoming then a course of treatment would seem rational to suggest.

Test Format	Antigen Used	Variation	Interpretation
western blot	merozoite lysate	none	14.5 kDa
western blot	merozoite lysate	quantification of csf to serum IgG levels	17 kDa
western blot	merozoite lysate	pre-blocking of blot with anti- <i>S. cruzi</i> IgG	16 and 30 kDa
IFA	whole merozoites	indirect fluorescent antibody	endpoint titer= last dilution showing whole parasite fluorescence; titer gives "probability" of EPM
ELISA	recombinant surface antigen	SAG1 ELISA	correlates given titer with likelihood of clinical disease
IgM -ELISA	merozoite lysate	IgM capture ELISA	Likely relates to acute phase [re]infection

A whole organism, indirect fluorescent antibody diagnostic test has also been tried but its diagnostic utility remains to be determined and additional testing of serum and CSF for IFA positivity may not add substantially enough to the post-test probability of diagnosis to make the additional costs warranted⁵⁴. Also, using ELISA tests to detect the presence of specific antibodies to *S. neurona* surface antigens [snSAG], sensitivity and specificity test results of about 95% and 93% respectively have been found⁵⁵. The IgM-capture ELISA may assist in identifying acute exposure even with the background of pre-existing antibody⁵⁶. Although detection of *S. neurona* DNA fragments in CSF is not in general very reliable, this test likely is useful in according a diagnosis of EPM in a horse suspected to have the disease but has negative for the presence of parasite specific antibody in CSF⁵⁷. Finally, detection of somewhat unique expression of equine RNA profiles in circulating leukocytes, although non specific for the response to *S. neurona* infection, has been introduced as a potential tool for detecting patients responding to an early pathogenic infection of the protozoa as opposed to a sub-clinical infection with *S. neurona* or to other common causes of equine neurologic disease⁵⁸.

To sum up testing for *S. neurona* infection in horses, the diagnosis of EPM in a horse which resides in or came from a region of the world where *S. neurona* completes its life cycle and which has definitive neurologic signs, is best supported by elimination of other neurologic diseases using appropriate diagnostic imaging, other serologic and toxicologic testing and CSF evaluation and detecting *S. neurona*-specific antibodies in appropriately collected CSF by WB or IFAT assays⁵³. Samples of CSF can be contaminated with $<10 \times 10^9$ RBCs/L and still test reliably for IFAT antibodies⁵². Additional, very useful analysis for *S. neurona*-specific DNA using PCR amplification from CSF can be reserved for those cases where the immunotesting is negative or equivocal⁵⁷. Outside those countries in which EPM is endemic, the negative predictive value of such tests in horses with signs of myeloencephalitis and a history of residing in the Americas in the past is likely to be extremely high. Thus a clinician should be able to rule out [active] EPM

in individual cases with negative tests. However, positive results to serum and CSF testing must be interpreted with the same diagnostic accuracy parameters as for horses in endemic countries.

Cervical Vertebral Malformation and Malarticulation [CVM]

Plain radiographs in CVM cases usually indicate combinations of stenosis of the vertebral canal which is often exaggerated by flexion or extension of the vertebrae, and osteoarthritis of the articular processes⁵⁹⁻⁶³. To obtain true lateral cervical radiographs the horse should be in a sedated, standing position with a handler positioned out of the radiographic beam and pulling forward on the patient's head collar to put added traction on the cervical vertebral column and thus straightening each vertebra along the median plain giving best alignment of vertebral bodies. Particularly in big sedated horses and especially with patients under general anesthesia, degrees of cervical torticollis result, which are difficult to correct for.

Many normal variations and inconsequential findings must be realized in interpreting cervical radiographs⁶¹⁻⁶³. Thus the frequent finding in *circa* 5% of thoroughbred and warmblood horses of transposition of ventral processes of C₆ on to C₅ and more often on to C₇ on one or both sides must be considered when vertebrae are being identified on radiographs⁶³ and at the time of any surgery. Other notable though usually inconsequential radiographic findings on equine cervical radiographs include:

- variations and asymmetry in the shape of the intervertebral notches or orifices at the cranial border of C₂;
- irregularities to the dorsal aspect of the caudal physes of C₂-C₇ projecting into the intervertebral space;
- separate ossification of the caudal projection of the transverse processes of C₆ [occasionally transferred on to C₅ or C₇];
- serpentine lucent vascular channels in the spine of C₂;
- irregular border to the caudal aspect of the spine of C₂;
- irregular size and contour to the dorsal border of the spines of C₃-C₆;
- circular 3-20mm, cyst-like lucencies of the arches and less often bodies of all cervical vertebrae;
- large and cranially projecting, irregularly-mineralized spine of C₇ [and T₁].

Because narrowing of the cervical vertebral canal and associated spinal cord compressive lesions in horses' necks are predominantly dorsoventral in orientation, measurements of minimal sagittal diameters [MSDs] have been used to compare a CVM candidate with a control population⁶⁴. These MSD measurements must be taken within a vertebra where the sagittal height of the canal is measured perpendicular to the floor of the canal [Figure 1] at its minimal value. This minimal value most often occurs near the cranial orifice but sometimes will be near the caudal orifice. Values approaching or lower than those for the control population [Table 1] strongly indicate that compression likely is occurring. Significant angular deformities, severe osteoarthritis, history or suspicion of trauma and indications that transverse compression could be occurring may individually also be indications to suspect narrowing of the vertebral canal and to possibly proceed with a contrast myelographic study.

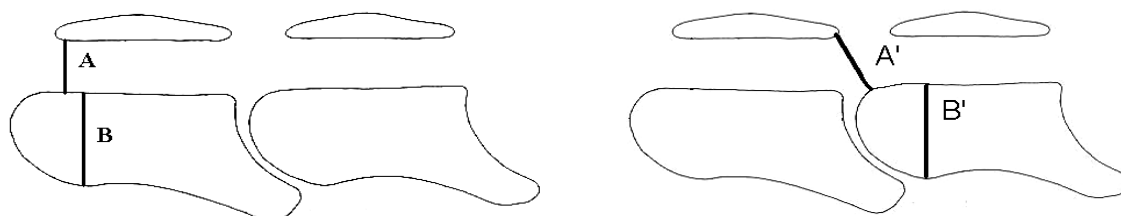


Figure 1: A = intravertebral minimal sagittal diameter
B & B' = vertebral body height
A/B = intravertebral minimal sagittal ratio
A'/B' = intervertebral minimal sagittal ratio




Figure 2: Some characteristics of CVM evident on radiographs and at post mortem examination include stenosis of the vertebral canal [bars], kyphosis [O], dorsal projection of epiphyses [*] and caudal extension of dorsal arch [curved arrows]. Degrees of articular osteochondrosis and osteoarthritis are not shown.

Table 1. Reference table for acceptable minimal, radiographic sagittal ratio [SR] values in horses [n=19] without CVM, to assist in assessing the likely presence of cervical spinal cord compression in ataxic, tetraparetic adult horses ⁶⁵.

Statistic	Intra- and inter-vertebral minimal SR values [mm] ⁶⁵										
	C2	C2-3	C3	C3-4	C4	C4-5	C5	C5-6	C6	C6-7	C7
mean	72	91	61	71	59	74	61	80	60	71	62
sd	7.9	11.7	5.6	9.3	5.4	11.1	5.4	9.5	6.2	8.8	5.2
Minimum	55	63	52	60	49	56	52	63	54	58	55
mean – 2sd	56	67	49	52	48	51	50	61	48	54	52

To correct for size of horse and for radiographic enlargement several concurrent radiographic measurements have been used as common denominators for correcting the absolute MSD measurements into corrected MSDs ⁶⁰. The most favored of these correction factors is the dorsal height of the cranial physal region at its maximum height, again measured perpendicular to the floor of the vertebral canal within that vertebra [Figure 1]. The ratio of the MSD to the height of the cranial physis of the same body [C₃ in the case of the axis] is referred to as the minimal intravertebral sagittal ratio [SR]. As a general rule of thumb horses with signs of cervical spinal cord disease that have SR values below 50% have a greatly increased risk of having cervical vertebral canal stenosis. With such a finding, and if there are other characteristics identified as in Figure 2 then CVM can be diagnosed with some degree of confidence. Of note here is that when developing reference ranges for MSD and SR values and when taking such measurements from radiographs of suspected cases of CVM, it must be clear which measurements are being taken. Firstly the minimal height of the vertebral canal within a vertebra may be anywhere along its length, not only near the cranial orifice. Secondly, with poor quality definition, under exposed radiographs the MSD often is measured smaller than when measured from high quality radiographs taken of the same vertebrae and when compared to measurements obtained at post mortem examination. This most often occurs at caudal cervical vertebral sites and usually it is because the ventral margins of the pedicles of the articular processes are misinterpreted as the dorsal margin of the vertebral canal itself. In this situation an imaginary line drawn cranially along the lamina of the roof of the canal within the vertebra is extended in a slightly dorsal curvature to mimic the normal contour of the cranial orifice and through the radiodense pedicles to indicate where the height of the MSD will be measured to. Interpretation of such measurements must be predicated by the admission that the radiographic image is of inferior quality.

The inclusion of intervertebral measurements for canal diameters [Figure 1] taken from standing lateral survey radiographs is likely to increase the discrimination of Types I and II CVM cases from non-CVM cases. These measurements can be corrected for horse size and radiographic magnification as has been done for the intravertebral sagittal ratios. Reference values can be developed for each diagnostic radiologic facility but as a guide Table 1 gives reference ranges for horses that were or were suspected to be ataxic and did not have cervical spinal cord compression based on full gross pathologic and neurohistologic evaluation. Notably, some of the SR cut-off points for this set of data using either mean less 2 SD or the absolute minimum values are below 50%.

Prior to deciding on any surgical interference, myelographic evidence of spinal cord compression is accepted as being mandatory. Positive contrast myelography under general anesthesia is not an innocuous procedure in the horse^{66, 67}. Hemorrhagic, aseptic, neutrophilic meningitis occurs 6 to 48 hours following the procedure, which can be associated with complicated recoveries (Beech, 1979) and often with fever^{66, 68}. Digital radiographic imaging, experience with the procedure, modern anesthetic protocols and newer nonionic, water-soluble contrast agents such as iopamidol and iohexol have vastly improved the safety of this procedure and quality of resulting radiographic images making even ventrodorsal views through the caudal cervical region quite useful⁶⁸⁻⁷⁰. Standing myelography in the conscious horse⁷¹ is an unnecessarily painful process such that it should be performed under general anesthesia.

Myelography is regarded as clinically necessary to demonstrate impingement on the spinal cord by a stenotic vertebral canal, by exuberant periarticular soft tissue or cyst and with or without additional dynamic flexion or extension positioning. Considerable care must be taken to not further compromise the spinal cord with excessive manipulation of the neck under general anesthesia. With manual flexion the dorsal and ventral contrast myelographic columns can be totally obliterated in normal foals. Although unequivocal spinal cord compression can readily be determined with myelography, often subjective evidence of contrast-column compromise exists, which is of questionable significance because of the lack of definitive, objective criteria^{62, 64, 67, 70, 72-74}. If a question is raised concerning the presence or not of a myelographic cervical spinal cord compression in a horse, then a degree of objectivity can be introduced by using minimal flexed dural sagittal diameter measurements, dorsal myelographic column reduction ratios and dural diameter reduction ratios^{60, 64, 72, 74-78}. These measurements are well described and need to be available for specialty practices prepared to undertake invasive cervical vertebral surgery on horses with CVM. The use of 50% reduction of dorsal myelographic contrast column has been purported to be a very good criteria for compressive spinal cord disease and indication for surgery^{73, 79-82}. However, it appears that this is not the case and it is agreed that a 50% reduction of the dorsal myelographic column should not be used alone to diagnose CVM, nor used alone to plan surgical treatment at a site of suspected compression^{72, 74, 76, 83}. Better diagnostic accuracy is achieved by using a 20% reduction of the total dural diameter reduction on a neutral myelographic view for the midcervical sites, and a 20% reduction of the same measurement at C6-7 with the neck in either neutral or flexed position⁷⁵. In this author's experience the use of absolute minimal neutral and flexed dural sagittal diameter measurements^{64, 76} still appear to be reasonably precise for defining the sites of spinal cord compression in cases of CVM and further data files should be forthcoming for this⁶⁵.

A group of workers in Japan have studied detailed relationships between morphologic measurements taken from cervical vertebrae in normal and CVM-affected young Thoroughbred horses^{84, 85}. These workers then correlated their measurements⁶⁴ with histologic lesions and found that the accuracy of radiographically diagnosing CVM was very good but not completely precise⁸⁶. Finally, they developed complex measurements of ratios of stenosis from plain survey radiographs [Ss] and from myelograms [Sm]⁷⁸. The Ss compared the average sagittal diameter of the vertebral canal measured in the middle of each of two adjacent vertebrae with the extrapolated dural height between these vertebrae as measured from extensions of lines drawn along each dorsal lamina of the vertebral canals in each vertebra. Likewise the Sm compared the average sagittal diameter of the dural space measured in the middle of each of two adjacent vertebrae with the minimal flexed dural sagittal diameter⁶⁴ between these adjacent vertebrae. The conclusions were that Ss and Sm measurements were useful for the clinical diagnosis of CVM⁷⁸.

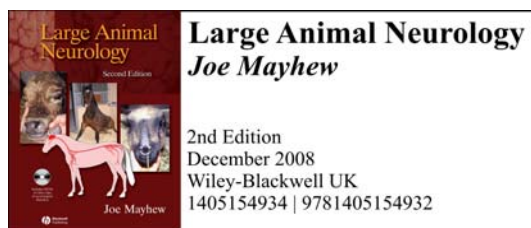
In summary, using the various subjective [Figure 2] and semiquantitated measurements Table 1 and Figure 1] and calculations discussed above, the presence or absence of pathologic narrowing of the vertebral canal and consequent spinal cord compression then can be stated with some confidence, backed by sensitivity and specificity accuracy parameters in the region of ~90%. In selecting criteria of high positive predictive value or high negative predictive value it behooves the radiologist and surgeon to decide whether advisable to err on the side of false positive diagnosis and perform an occasional unnecessary surgical procedure or on the side of false negative diagnosis and leave a possibly surgically amenable compressive site unattended.

As indicated, occasionally the compression in both Type I and Type II CVM cases can be transverse rather than dorsoventral. In Type I cases this is usually due to a kyphotic angular deformity [Figure 2] between C2-3, C3-4 or occasionally C4-5^{63, 76, 77}. This is associated with ventral positioning of the pedicles and articular processes bringing the latter level with the lateral aspects of the spinal cord^{64, 83}. In horses with CVM, Many times the intervertebral SR will still be abnormal even if the intravertebral SR measurement is not. Likewise in Type II cases with transverse compression the sagittal ratios are often small and prominent osteoarthropathy usually is present. On lateral myelography of these cases the dorsal and ventral contrast columns may not appear compressed and the minimal flexed dural sagittal diameter measurement may not be too small. However, a blanching of the overall contrast column, widening of the sagittal shadow of the spinal cord and sometimes the presence of two dorsal borders to the contrast column, due to asymmetric dorsolateral intrusion of articular tissues, indicates spinal cord compression. This occurs most often at C₆₋₇ and C₇-T₁^{64, 83}.

Thus, measurements taken from high quality, true lateral, standing radiographs of the neck from the base of the skull to T1 can be used to predict reasonably well the presence of current or recent spinal cord compression in a wobbler. If surgery is an option in an individual case then myelography is to be recommended to help confirm current compression of the spinal cord at a particular site or sites, or to attempt to negate this possibility. If no compression is deemed to be present and surgery is not thus an option then a decision is required as to whether to euthanize the patient under anesthesia or to progress to specific therapy for another disease.

For surveillance purposes, using reference values [Table 1] for MSDs and corrected MSDs for young thoroughbred foals^{65, 87}, and incorporating them with semiquantitative grading of the contributing structural changes evident from plain cervical radiographs [Figure 2], a score for the status of individual foals with respect to the likelihood of development of CVM was developed. Using such a CVM score it was possible to predict the onset of signs of spinal cord disease in young thoroughbred foals that were graded with a CVM score above the reference ranges^{87, 88}. Whether such a CVM scoring system would be of general predictive value requires further clinical and pathologic data acquisition and analysis.

In conclusion, when evaluating wobblers suspected to suffer from CVM, clinicians, radiologists and surgeons must be aware that, although use of measurements taken from radiographs can improve the accuracy of diagnosis of CVM, there are not infallible, premortem diagnostic tests for the presence and absence of previous and current compression of the spinal cord. A decision must be made as to whether one minimizes the chance of recommending surgery on a horse [vertebral site] that does not require it OR minimizing the chance of failing to give the best chance of stopping progression of spinal cord compression. The attitude to performance horses undergoing surgical fusion of cervical vertebrae varies in different countries and such an atmosphere must also be considered when advising on outcomes for wobblers suspected of having cervical spinal cord compression due to CVM.



References on request