

AFTER THE CRASH – LESSONS FROM CHRONIC LAMINITIS

Professor Christopher C. Pollitt. BVSc, PhD.

Australian Equine Laminitis Research Unit

School of Veterinary Science

Faculty of Natural Resources, Agriculture and Veterinary Science

The University of Queensland

Qld 4072 AUSTRALIA

c.pollitt@uq.edu.au

www.laminitisresearch.org

The internal, anatomical disintegration of the hoof, which accompanies the acute episode, is initially, invisible to the naked eye. With the passage of time however the hoof begins to display the effects wrought upon it by the pathology of the acute phase. If the initial lamellar pathology is mild the clinical signs of laminitis may abate as the distal phalanx lamellar attachment apparatus repairs. Horses recovering from even the mildest laminitis should be rested and observed closely. If no radiographic evidence of palmar displacement of the distal phalanx within the hoof capsule exists, and the digital pulse is not palpably exaggerated 48 hours after treatment has ceased, the horse can be cautiously returned to its usual function. However if lameness persists and worsens this means that there is on-going displacement of the distal phalanx within the hoof capsule. This process of increasing chronicity after the crash needs to be understood to if we are to care for foundered horses effectively.

Coronary band changes

When the majority of the lamellar attachments fail, as they do in severe cases (sinkers), the distal phalanx descends deeply into the hoof capsule, taking with it the attached coronary band connective tissue. This creates a deficit in the coronary band and the sharp

edge of the proximal hoof wall becomes palpable with a finger. Initially the deficit may be palpable only dorsally (the front of the foot), over the extensor process of the distal phalanx. If it extends around the coronet to the quarters and heels, the prognosis is grave as this is an indication that most of lamellar attachment apparatus is destroyed. Sometimes the skin may separate at the hair-line of the coronet and exude serum (Fig 1).

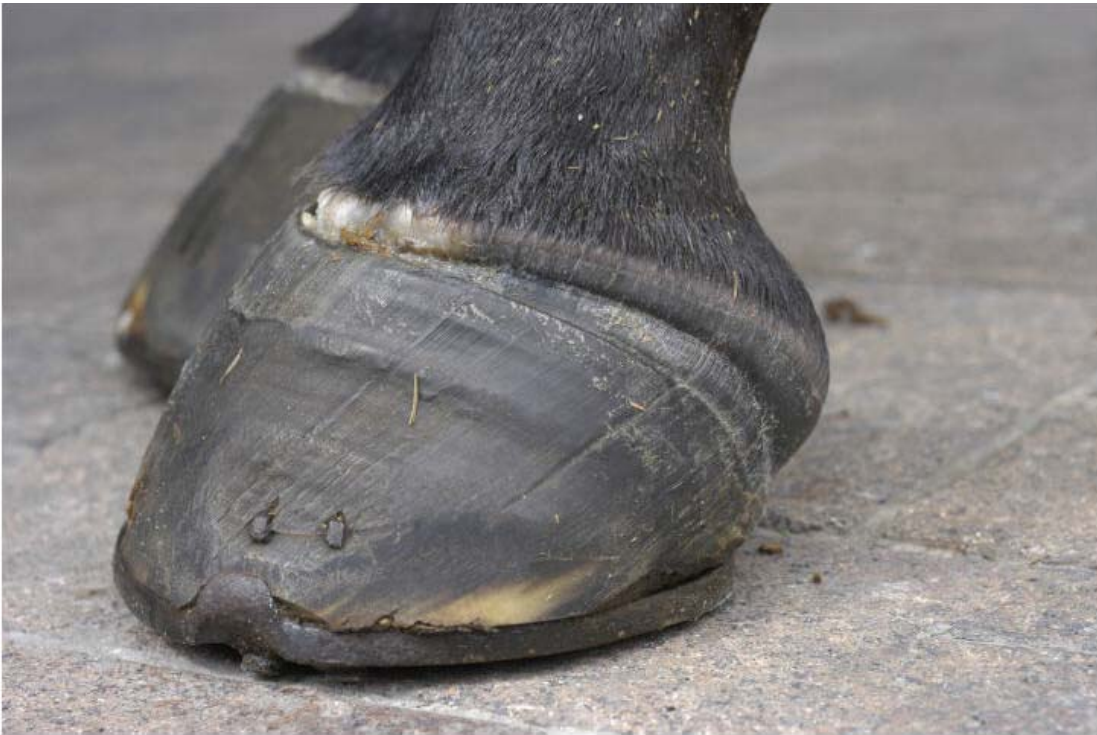

Fig 1. Mare 3 months after developing metritis post retained placenta. The coronet is deformed and exuding serum at the hair line.

Sole changes

Within a few days of the acute episode, a convex bulge in the sole (the so-called dropped sole) may appear beneath the descending distal phalanx. Initially, fine cracks appear over the bulge in the sole and in severe, deteriorating cases the resultant pressure necrosis causes the distal phalanx to prolapse completely through the horny sole (Fig 2).

In less severe cases, where descent or rotation of the distal phalanx has been slight, the sole may lose its normal concave appearance and be flat. Careful shaving of the sole, with a sharp hoof knife, may reveal a red, crescent-shaped bruise. This is evidence of trauma from within, inflicted on the sole by the descending margin of the distal phalanx which is also crescent shaped. Haemorrhage from blood vessels in the solar corium, crushed under the distal margin of the bone, releases haemoglobin that stains the horny sole. The red stain appears at the ground surface of the sole after a period of sole growth. Bilateral, crescent-shaped bruising of the sole must not be dismissed as “stone bruising”.

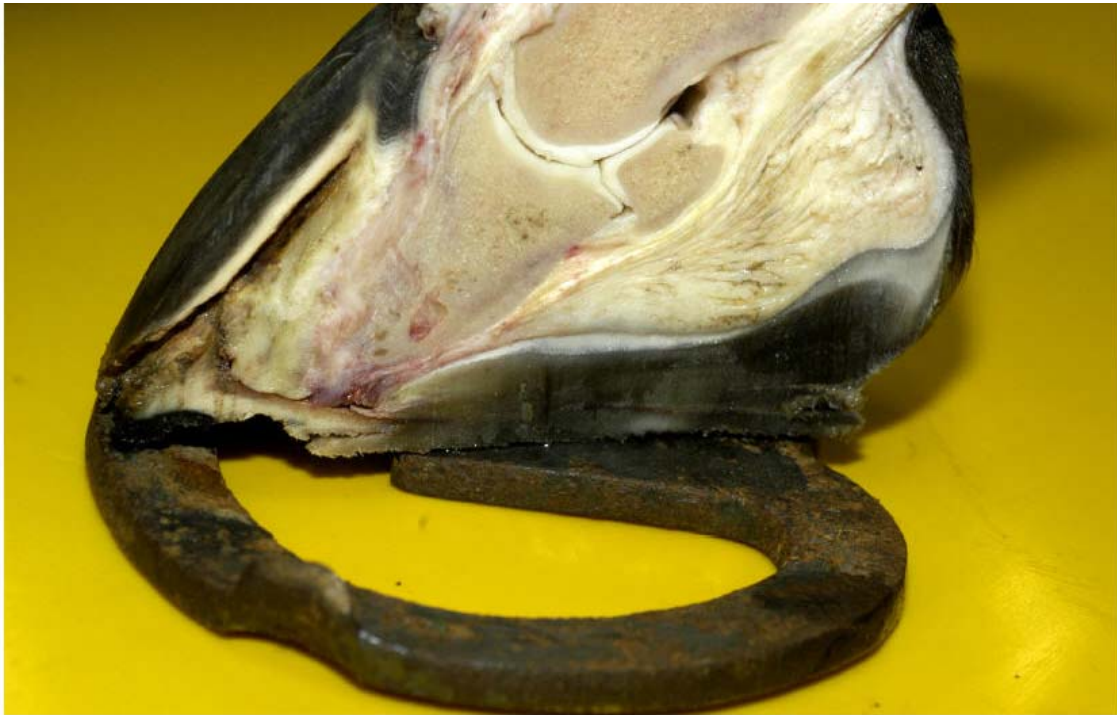

Fig 2. The foot of the same mare as in Fig 1 showing the extent of chronic laminitis internal damage. The sole has bulged downward and the distal phalanx has perforated the sole.

Hoof wall changes

After the acute episode of laminitis and the consequent shift in the position of the distal phalanx within the hoof capsule, the horse is left with a legacy of deformed hoof growth. Dorsal hoof wall growth is retarded, while growth at the heels proceeds at the normal rate. In the normal hoof, minor fluctuations in growth rate produce in the wall a series of

concentric rings, parallel to the coronet, clearly visible on the surface of the hoof. In a hoof affected by chronic laminitis the growth rings are no longer parallel; they converge at the toe where the growth rate is least. In severe cases, the divergency of growth between toe and heel produces a dramatic upturning of the toe and the hooves take on the appearance described as “Aladdin’s slippers” (Fig 3).




Fig 3. Chronically foundered pony with “Aladdin’s slipper” feet.

If neglected, toes affected by chronic laminitis can become unnaturally long and make locomotion for the foundered horse or pony extremely difficult. During the acute phase, when the lamellar attachment apparatus fails, the descending distal phalanx takes with it the dermal papillae of the coronary groove. The normally straight papillae become kinked, but the basal cells of the coronary epidermis continue to elaborate hoof wall, but now in distorted direction. The kink imposed on the papillae is reflected in the hoof wall tubules: they are kinked too. After the acute episode the coronet usually recovers to some extent and produces hoof tubules with a more correct orientation. However, the kinked tubules; remain in the hoof wall until they grow out at the ground surface. Kinked hoof wall tubules can be seen in sections of chronically foundered feet post mortem (Fig 4).

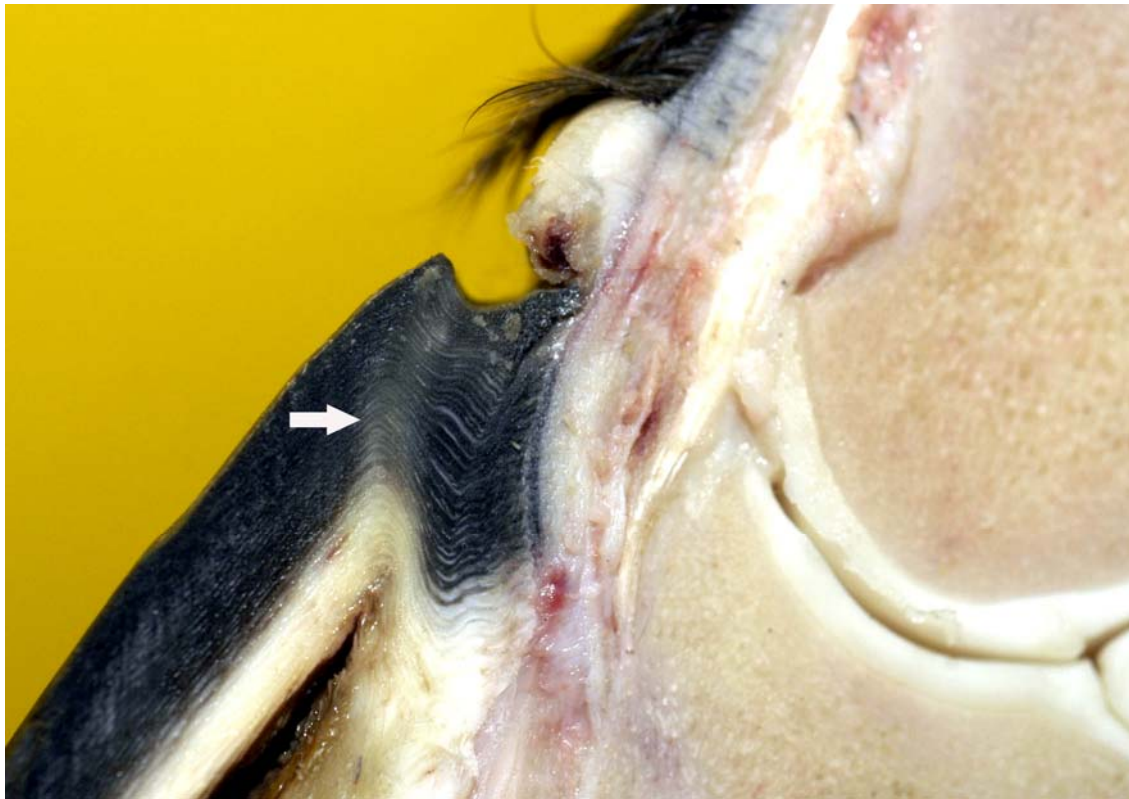


Fig 4. Kinked hoof wall tubules in a chronically foundered hoof. Prior to laminitis the hoof wall tubules (arrow) were straight and parallel.

A groove in the hoof wall, corresponding to the zone of kinked tubules, is visible on the surface of the hoof wall. The depth of the groove gives some indication of the severity of the acute episode. The distance of the groove from the coronet can be used to estimate (based on a normal hoof wall growth rate of 7 mm/month) the retrospective timing of the acute episode.

Hoof wall lamellar changes.

Ultimately it is the strength of the lamellar interface that determines prognosis. Many horses relapse after the initial laminitis episode despite early signs of improvement and we need better strategies for managing laminitis affected feet. Thus we studied laminitis affected tissue 7 days after the initiating episode to assess the healing response to the disease.

Surprisingly, 7 days after laminitis, the destructive enzymatic processes that caused lamellar basement membrane (BM) dysadhesion and lysis, basal cell dislocation and lamellar attenuation had abated. All epidermal compartments were enveloped in normal appearing BM and the majority of epidermal basal cells (EBCs) were of normal shape and orientation. The major abnormality was the spectacular change in lamellar architecture. Lamellar anatomy was in disarray. The rows of organised, symmetrical hoof wall lamellae that characterize normal lamellae had been replaced with epidermal strands and islands, many no longer connected to their respective primary hoof wall lamellae. The lamellae had clearly lost their capacity to function as an attachment apparatus between hoof wall and bone. Premature resumption of athletic exercise and thus greater foot break-over strain, particularly in the fore feet, would rupture surviving lamellar attachments. This is the likely mechanism behind the notorious exacerbations that plague horses apparently recovered from a primary bout of laminitis.

The lamellae become measurably stretched and elongated (Fig 5) causing the distal phalanx to sink into the hoof capsule. Initially this results in a small but significant increase in distance, measurable on radiographs, between the outer hoof wall and the upper surface of the distal phalanx. This emphasises the importance of good quality radiographs to assess the severity of the initial laminitis insult. Even a small increase in the distance between the hoof wall and the distal phalanx indicates to the practitioner that histopathological changes have occurred. Early radiographs can be used as a yardstick against which to measure any subsequent exacerbation.

The empty compartments of dislocated BM, so obvious from in the acute stages of acute laminitis (Pollitt 1996; French & Pollitt 2003 etc) are colonised by surviving epidermal cells and produce spheres and discs of isolated epidermal SEL remnants. The outright lysis of lamellar BM that occurs adjacent to the PEL (Pollitt & Daradka 1998) is the reason why the islands of epidermal tissue become stranded in the lamellar dermis. Laminitis, observed 7 days after induction, reduces the surface area of the lamellar attachment apparatus and weakens it.

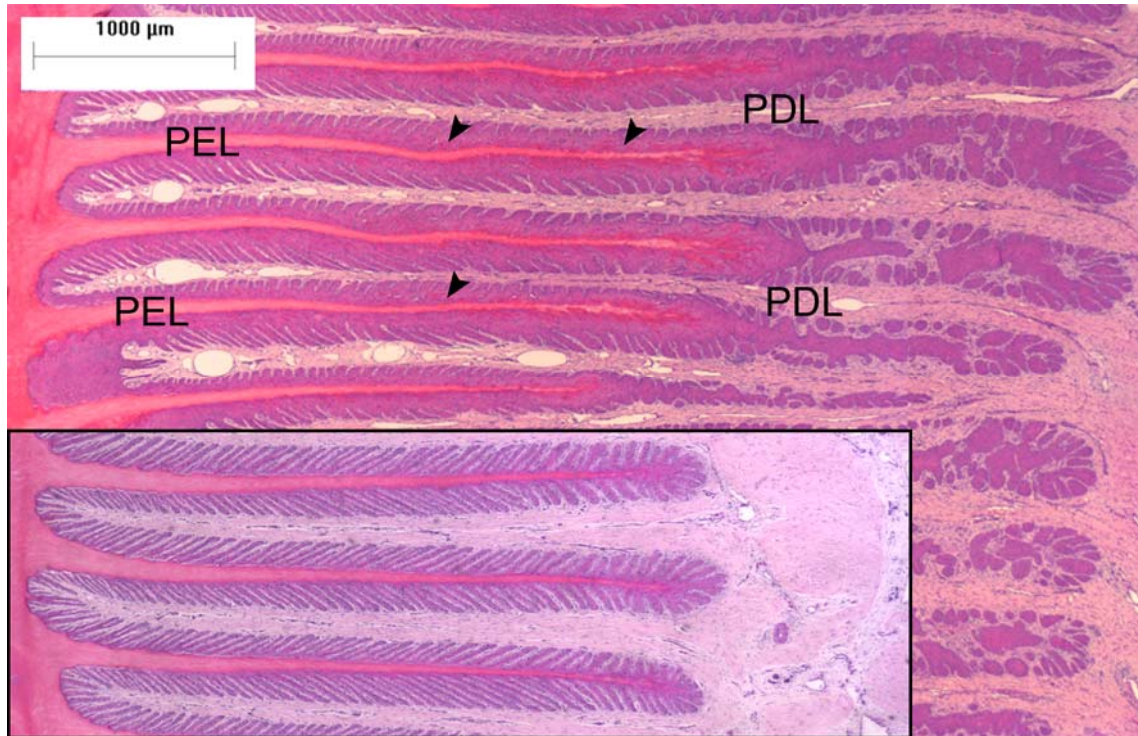


Fig 5. Photomicrograph of left fore hoof lamellae 7 days after laminitis induction. Inset, at the same magnification, shows lamellae from normal control horse. The primary epidermal lamellae (PELs) affected by laminitis are longer than normal. The keratinised axis of the PELs is relatively unaffected but on either side of it are abnormal columns of partially keratinised epidermal cells (arrowheads).

The formation of a lamellar wedge is often described as a hallmark of chronic laminitis (Roberts et al 1980) but there was no sign that one was forming at the 7d stage of the disease. Presumably the wedge forms as a consequence of unstable lamellar attachments.

Diagnosis

It is not difficult to make a presumptive diagnosis of laminitis, based on history, the characteristic clinical signs and a physical examination of the feet. However, the additional data generated by good quality radiographs will allow a final decision regarding severity, chronicity, type of treatment and prognosis to be made with more confidence. A radiographic examination of the feet is an essential step in the diagnostic

work-up of the laminitis case. Whenever possible, radiographs should be made as soon as the clinical signs of laminitis appear. An early appreciation of the subtle, radiographic changes of acute laminitis may enable further deterioration to be halted if treatment procedures are instituted promptly. It is also important to take serial radiographs so that the effectiveness of treatment, or conversely, deterioration, can be monitored over a period of time. The owners of horses that are foundering must be kept up to date with the clinical status of their animal. In the critical, early stages of laminitis where the final outcome depends so much on the extent of the acute lamellar pathology, every effort must be made to mechanically support the damaged lamellar attachment apparatus. Radiographs enable the status of the relationship between the distal phalanx and dorsal hoof wall to be assessed with precision.

Radiology of chronic laminitis

As the histopathology of laminitis clearly shows, the major feature of acute laminitis is a progressive increase in the distance between the hoof wall and the distal phalanx. Initially this distance is microscopic in scale, but rapidly progresses to a separation measurable in millimeters. In radiological terms, this translates to an increase in the distance between the outer hoof wall and the upper surface of the distal phalanx; for convenience, the hoof, distal phalangeal distance (HDPD). The HDPD never varies in normal horses (Fig 6). If the HDPD increases, laminitis is the likely cause and it is extremely important to know the rate and magnitude of the HDPD increase. Good quality radiographs, documenting the shifting status of the distal phalanx within the hoof capsule, supply important diagnostic and prognostic information and should be part of the work-up of every laminitis case.

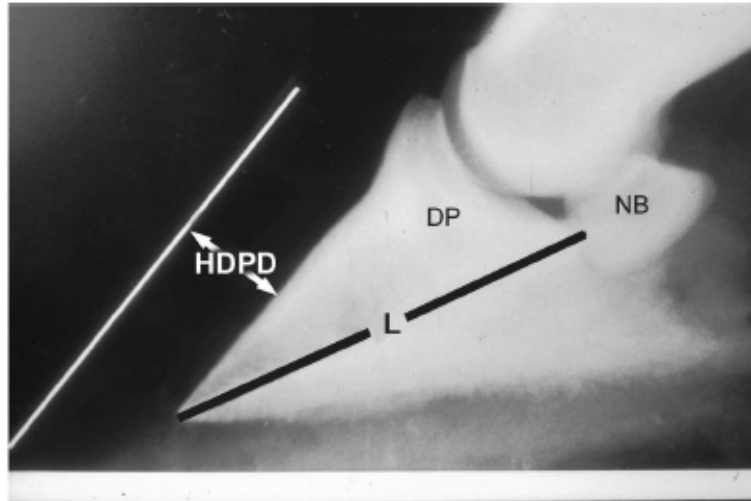


Fig 6. The distance between the radiopaque rod taped to the surface of the hoof wall and upper edge of the distal phalanx is the hoof, distal phalanx distance (HDPD). It is normally 15-17 mm in horses weighing 400-450kg.

A straight metal marker (a 50-70 mm steel rod or a horseshoe nail) should be taped to the surface of the dorsal hoof wall, to locate the outer surface of the dorsal hoof wall on the radiograph. Another marker, usually a drawing pin or thumbtack, should be inserted into the apex of the frog as an anatomical reference for subsequent shoe fitting. For the majority of normal horses in the 400-450 kg bodyweight range, the mid-wall HDPD (the distance between the marker and the outer edge of the distal phalanx) is between 15-17mm on radiographs uncorrected for magnification error. The hoof wall and the dorsal cortex of the distal phalanx are parallel in the normal horse.

Radiographs of horses or ponies, in the acute/early chronic stage of laminitis, should be examined for an increase in the HDPD (Fig 7). An increase of just 2-3 mm is extremely significant in the context of early chronic laminitis. In the first few days of the chronic phase, the hoof wall and the distal phalanx will draw apart, but remain parallel.

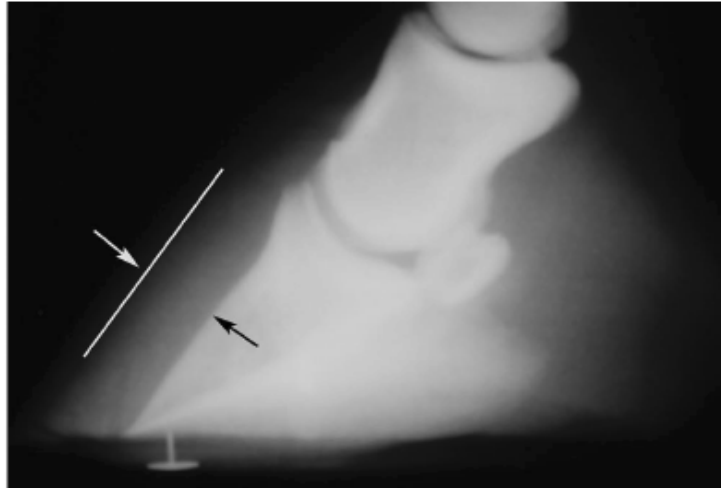


Fig 7. Radiograph of a foot with early, chronic laminitis. The HDPD has increased to 21mm indicating that severe laminitis has occurred even though there is no rotation of the distal phalanx.

Rotation of the distal phalanx occurs later. A valid diagnosis of early chronic laminitis can be made on the basis of a small increase in the HDPD. With an early diagnosis, prevention of any further increase by the application of the correct medical and supportive shoeing strategies may be possible. It is a mistake to let rotation of the distal phalanx be the sole diagnostic criterion of chronic laminitis - the diagnosis can be made earlier than this with good quality radiographs. Early diagnosis and early treatment can produce a better outcome.

With increasing chronicity, the distal phalanx continues to sink and move away from the hoof wall. The tip of the distal phalanx gradually rotates away from the dorsal hoof wall and begins to compress the corium of the sole; the tip of the distal phalanx gets closer to the ground. As pressure between bone and sole increases, the sole undergoes necrosis and the tip of the bone slowly disappears (osteolysis). Lateral radiographs show the degree of rotation of the distal phalanx. However it is the severity of pain and lameness at the time laminitis is first detected that more reliably predicts the outcome for the horse. Most veterinarians agree that the Obel system for grading the lameness of laminitis takes precedence over the radiographic determination of distal phalanx rotation for predicting final outcome. Our good correlation between the extent and severity of histological,

lamellar damage and grade of lameness supports this view. Nevertheless there is a correlation between the amount of rotation and the chance of returning to athletic performance. Horses with mild rotation may return to athletic function. Those with severe rotation (>11.5 degrees) lose their capacity to perform, remain crippled, and may have to be euthanased because of intractable pain and crippling.

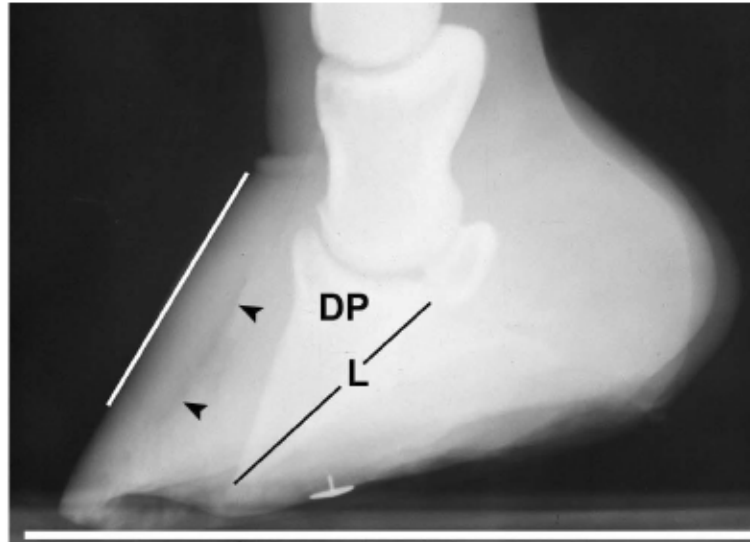


Fig 8. Radiograph of a foot with chronic, severe laminitis. The distal phalanx has sunk deeply into the hoof capsule and is close to the ground surface. The distal phalanx has rotated away from the hoof wall and the HDPD is 27mm (normal=17mm).

In addition to rotation, the distal phalanx should be examined radiographically for bone remodeling, distal margin fractures, osteolysis and osteomyelitis. These changes take several weeks to develop after the onset of laminitis and when present indicate that the horse is well into the chronic stage. They occur at the tip of the rotating distal phalanx where downward pressure against the sole, or in severe cases the ground, is at its greatest. In mild chronic laminitis, where palmar rotation is minimal (<5.5 degrees) the tip of the distal phalanx remodels and appears “ski-tipped” in lateral radiographs. Rapid, extensive decalcification of bone accompanies severe palmar rotation of the distal phalanx (>11.5 degrees) and such horses are poor candidates for rehabilitation.

Venography of chronic laminitis

Because there are no valves in the veins of the horse's foot an intravenous injection of x-ray contrast material into a digital vein produces a picture of the circulation called a venogram (Fig 9).

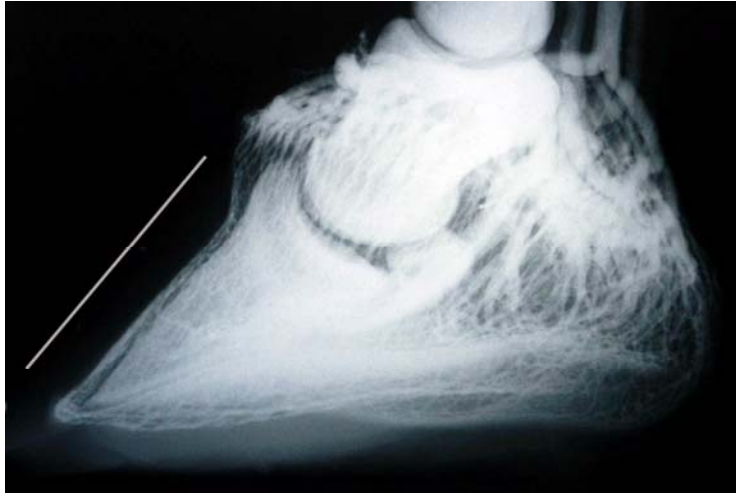

Fig 9. Venogram of the foot of a normal horse. There is complete filling of the coronet, lamellar, toe and sole venous circulations. The hoof wall and the distal phalanx are parallel and the normal, 17mm distance from each other.

Horses with severe laminitis develop progressively greater venographic changes (especially filling deficits). Serial venography gives important information into otherwise non-visible vascular pathology. Venographic changes occur in virtually all cases of clinical laminitis often when subtle plain radiographic changes are inconclusive. Venography of chronic laminitis supplies additional information about the magnitude of the anatomical changes that have occurred and is thus superior to plain radiography. Venography contributes to the development of more effective laminitis case management.

Chronic cases of laminitis develop venogram filling deficits. Insignificant initially they become more complete as the weeks go by. At 7 weeks there are usually prominent deficits in the coronary band and toe venous circulations (Fig 10). These progressively worsen until, in some cases, the entire dorsal wall appears to have no venous circulation. Histological studies show the reason for the venous filling deficits. The veins in the

region of the deficits are compressed, as if squeezed shut (Fig 11). The neighbouring arteries appear unaffected.

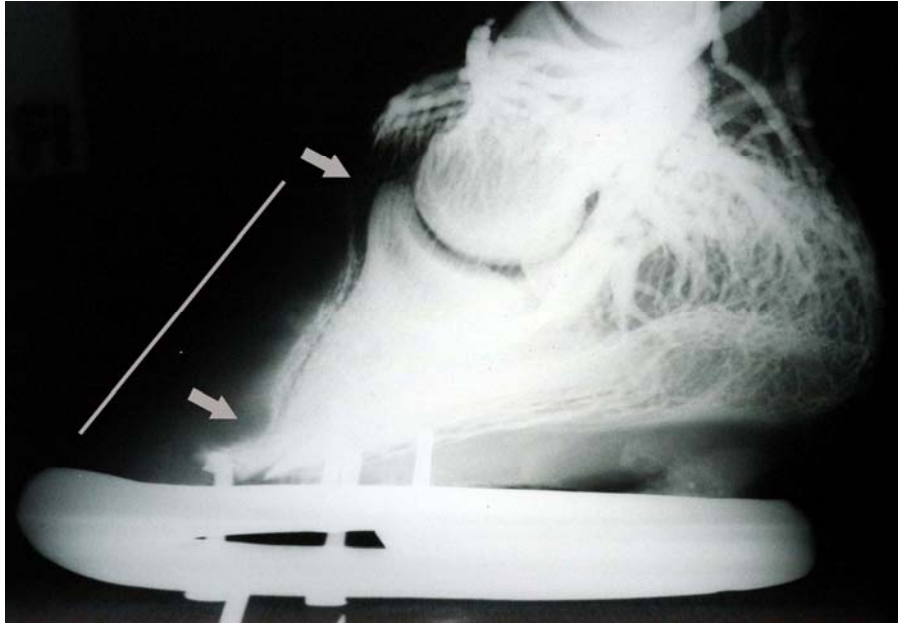


Fig 10. *Venogram of foot with severe chronic laminitis. The distal phalanx has rotated and is 32mm from the outer hoof wall. There are filling deficits at the coronet and toe (arrowed).*

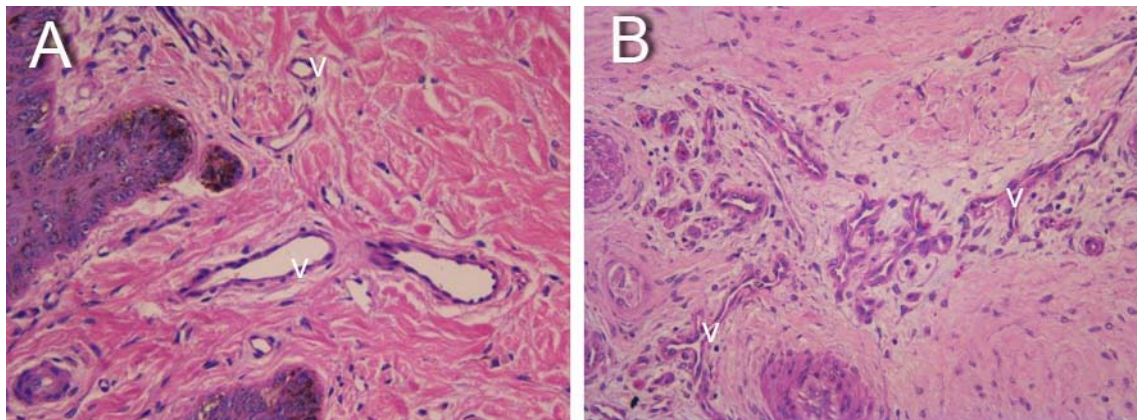


Fig 11. *Histology of normal coronary band veins (A) and veins affected by severe chronic laminitis (B). With chronic laminitis the veins (v) are compressed and flat.*

Why are the veins flattened and non-functional at the coronet? When the lamellar attachments fail the distal phalanx descends and drags with it the growth zone of the

proximal hoof wall. The growth zone continues proliferation of new hoof wall but now in a kinked pattern (Fig 4). In severe cases the growth zone sinks below the pre-laminitis hoof wall and in this trapped situation produces hoof wall that grows inwards. The in-growing coronet of chronic laminitis feet compresses the coronary cushion (Fig 12B) and exerts unrelenting pressure on the coronary vasculature that is probably pathological.

We have profiled the coronary cushions of a large number of chronic laminitis feet to understand the sequence of events that lead to incurable demolition of foot architecture. The coronary cushion is defined as the space between the proximal hoof wall and the extensor process of the distal phalanx. When sectioned in the sagittal plane, feet with normal venograms, have coronary cushions with broad, triangular profiles and hoof tubules that are straight and parallel (Fig 12A). Feet affected by chronic laminitis however have flattened, compressed coronary profiles, kinked hoof wall tubules and growth zones that are below the level of the pre-laminitis wall (Fig 12B).

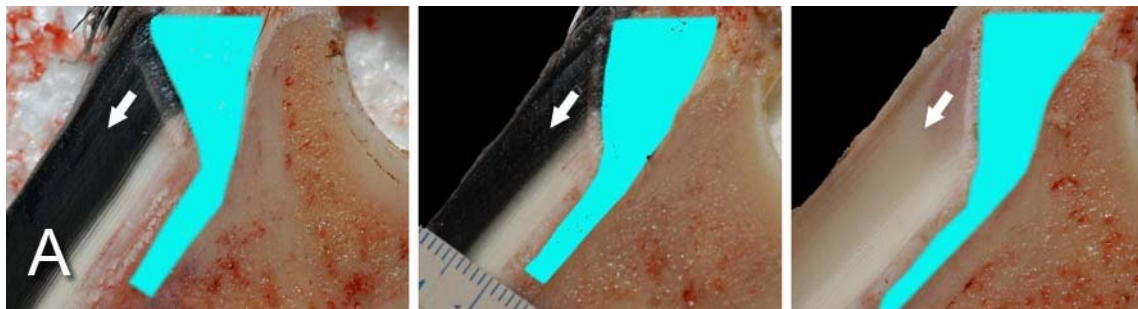


Fig 12A. Coronary cushion of normal feet. The profiles are triangular in shape and hoof tubules are straight and parallel. Hoof wall growth is normal and in the direction of the arrows.

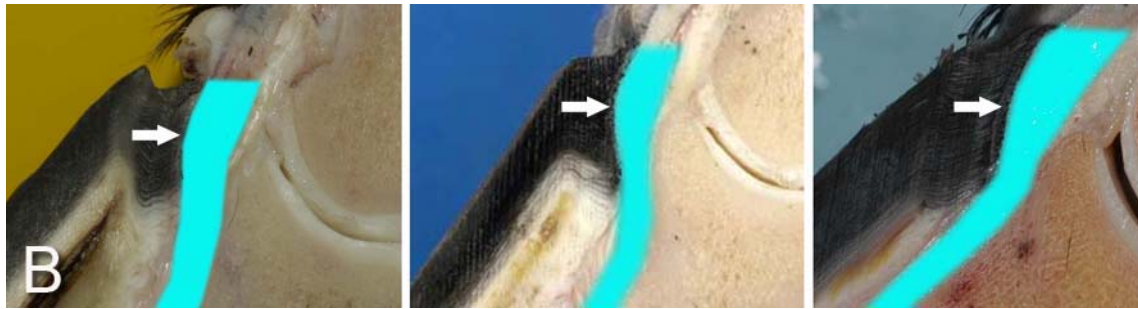

Fig 12B. *Coronary cushion of chronic laminitis feet. The profiles are reduced in size because the proximal hoof wall is growing inwards (in the direction of the arrows) and compressing the coronary cushion.*

Similar events occur at the toe. When the distal tip of the distal phalanx descends into the hoof capsule it not only crushes the sole corium but drags downwards the growth zone of the toe and terminal papillae. As with the coronet this growth zone continues to proliferate but instead of the normal downwards direction (Fig 13A) it grows inwards towards the tip of the distal phalanx. Here the pathological changes are more obvious. Not only are veins compressed the pressure is sufficient to lyse (destroy) the tip of the distal phalanx (Fig 13B).

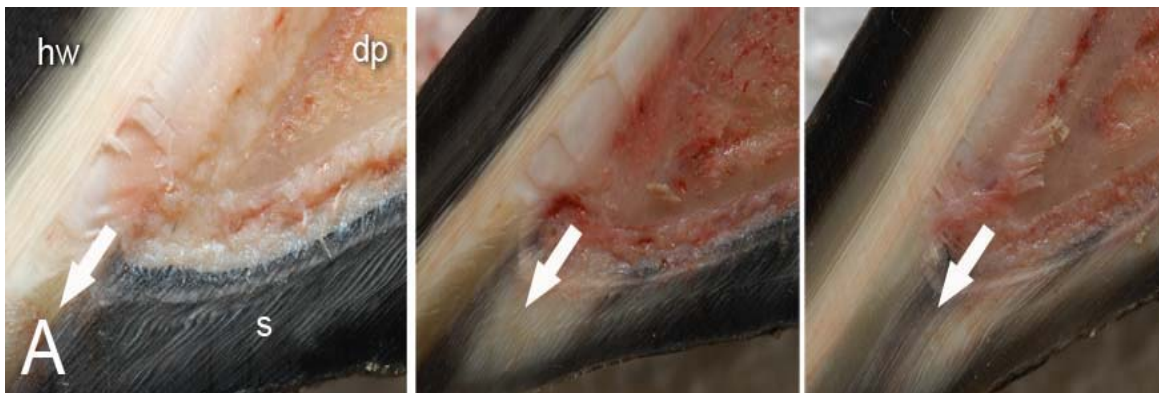


Fig 13A. *The toe and terminal wall tubules of normal feet are straight and parallel and growing downwards in the direction of the arrow.*

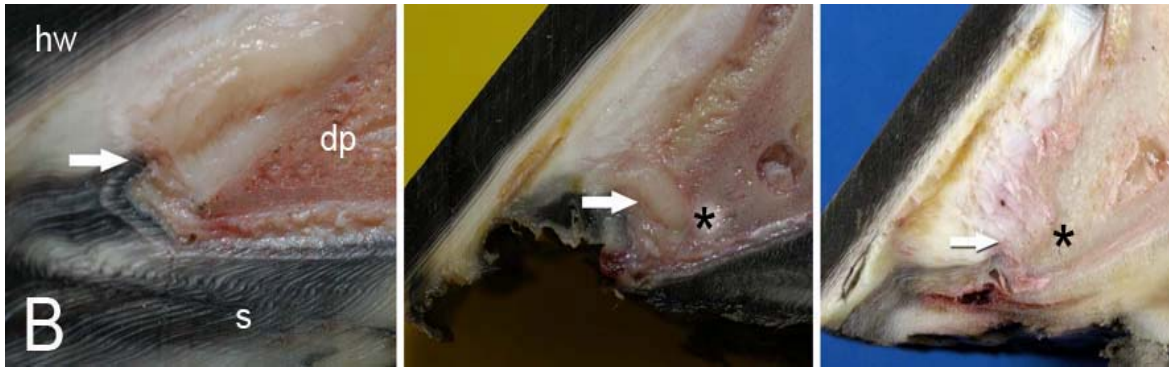


Fig 13B. The toe and terminal wall tubules of feet with severe, chronic laminitis are kinked and growing inwards, towards the distal phalanx, in the direction of the arrow. The unrelenting pressure of the inward growing hoof causes lysis of the distal phalanx (asterisk). Hoof wall = hw, distal phalanx = dp, sole = s.

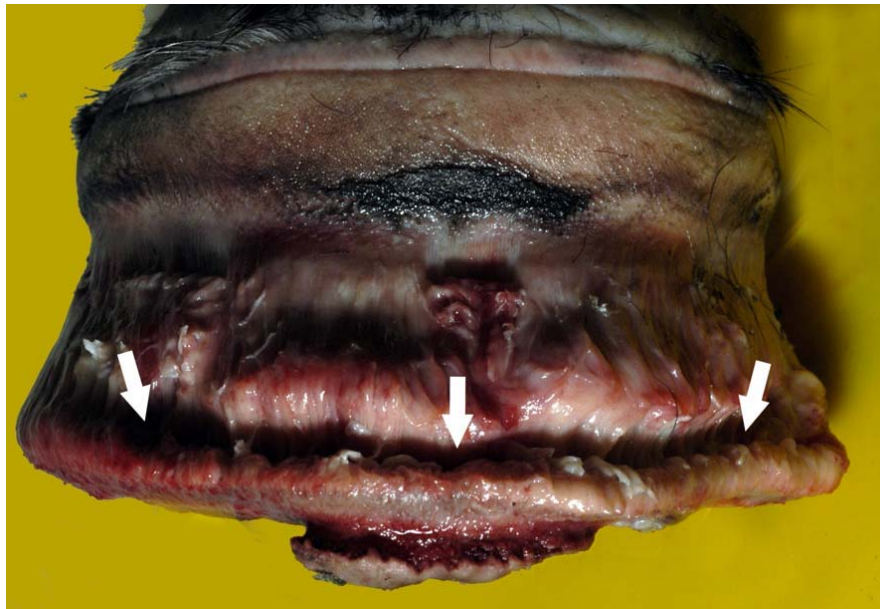


Fig 14. The foot of a chronically foundered horse with the hoof removed. The in-growing toe and terminal wall has severely compressed a band (arrowed) of lamellar corium that extends across the front half of the foot.

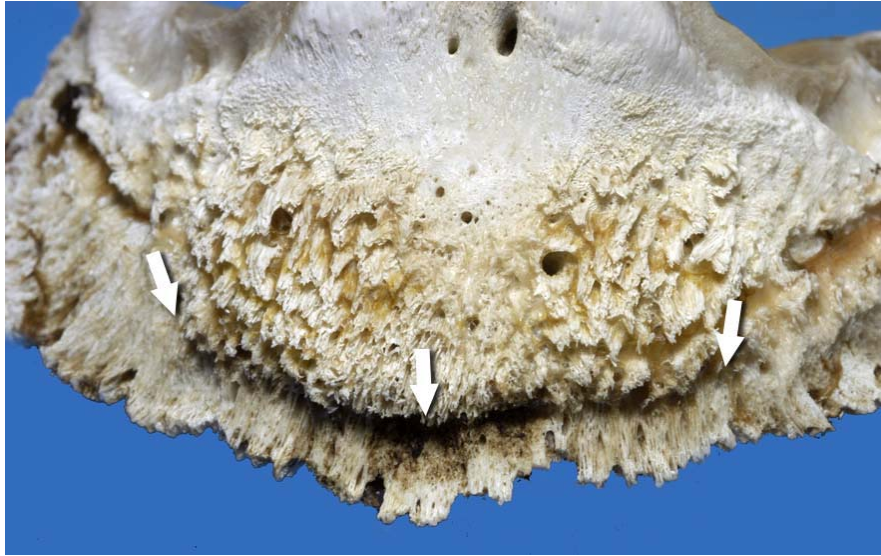

Fig 15. The distal phalanx of the same chronically foundered horse as in Fig 14. The band of in-growing toe and terminal wall has caused extensive lysis of the distal margin of the bone (arrowed).

The band of hard inward growing toe and terminal wall tubules encircles the front half of the foot (Fig 14) and may contribute to inexorable rotation of the distal phalanx; the band of hoof slowly pushing the tip of the bone backwards and downwards. This is contrary to the widely held belief that it is the pull of the deep flexor tendon that causes distal phalanx rotation. Soft tissue and vascular compression and bone lysis (Fig 15) of this magnitude is undoubtedly painful and must contribute to the obvious lameness of chronically foundered horses. If left unchecked the inward growing hoof of the proximal and distal hoof wall progressively destroys foot architecture eventually leading to incurable pathology. Early resection of the hoof wall in a zone corresponding to the in-growing coronet and toe (Figs 16 &17) appears to release compression of the tissues beneath and, depending on the extent of the soft tissue and bone pathology, restore a semblance of normal hoof growth.



Fig 16. Grooving of the coronet using the edge of a rasp. A 2 cm wide groove is made parallel and about 1 – 1.5 cm distal to the hair line of the coronet. The groove is deepened until the underlying horn is compressible with by thumb pressure. Local anaesthesia is not required. A motorized rotating bur (Dremel) can also be used to resect the deformed hoof wall.




Fig 17. Grooving of the coronet and distal toe, of hooves affected by chronic laminitis, aids restoration of normal hoof growth. Dorsal and lateral views of the 2 cm wide groove below the coronet and the resection of the distal toe is shown in A and B respectively. The shoe is a custom made aluminium heart-bar, with a leather pad and silicone palmar sole support fitted with reference to radiographic measurements.

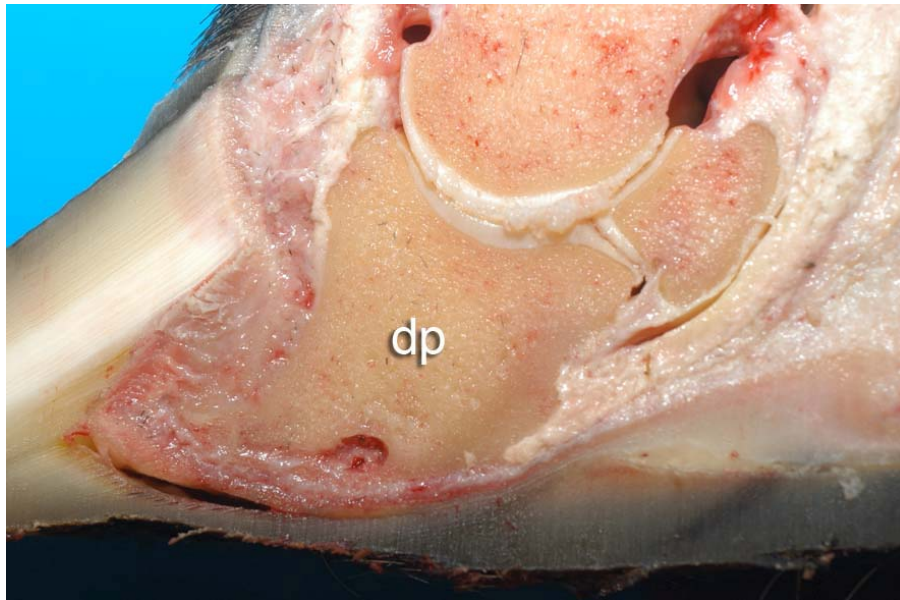


Fig 18. The foot of a horse with severe chronic laminitis of long standing. There is extensive remodeling of the tip of the distal phalanx (dp). The convex sole is weight bearing.

Prolapse of the distal phalanx through the sole of the foot is usually accompanied by infection. The sole may be under-run and gas lines delineating the solar corium may be visible on lateral radiographs. Osteomyelitis of the distal phalanx and abscess formation may cause pus and gas to discharge from the coronet. In chronic laminitis of long standing there can be spectacular de-mineralization of the distal phalanx and destruction of foot architecture (Fig 18).

Laminitic horses with significant initial lamellar destruction, as manifest by radiographic displacement of the distal phalanx, appear never to make a complete anatomical recovery and are prone to recurrent episodes of foot pain. Ultimately, the prognosis is directly proportional to the severity and extent of lamellar pathology. Horses with more than 15 degrees of rotation, accompanied by downward displacement of the distal phalanx into the hoof capsule within 4-6 weeks of the initial episode of laminitis, have a poor prognosis. Prolapse of the distal phalanx through an already necrotic sole, accompanied by subsolar and sublamellar infection, usually occurs. Pus will discharge from the coronet and the heels. Osteomyelitis and lysis of the distal margin of the distal phalanx will develop. Such cases will require months of expensive supportive care and surgery and although the occasional horse does make a surprisingly good recovery, most suffer months of crippling foot pain and recumbency, and eventually require euthanasia on humane grounds.

Outcomes

The road to recovery after a serious bout of laminitis is a rocky one. The extent of the lamellar pathology lies hidden beneath the hoof wall and we can only guess at what is really going on. Radiographs and the initial degree of pain expressed by the horse (often masked by pain-killers such as phenylbutazone) give valuable clues. Rapid sinking of the distal phalanx into the hoof capsule and involvement of all four feet make recovery unlikely. If the horse is clearly more mobile and comfortable after shoeing, this is a sign that the chosen therapeutic technique is working. Over time, the red, necrotic solar

corium, beneath the displaced tip of the distal phalanx, will re-epithelialise; turning light yellow in colour as new horn cells colonize the damaged area. The reappearance of thick, concave sole is an encouraging development. A return of hoof growth parallel to the coronary band especially at the front of the foot is also encouraging. Many horses recover to be sound enough for breeding purposes or paddock retirement. They will however require prolonged aftercare in the form of frequent expert shoeing and perhaps confinement to a personal yard. A few return to former athletic soundness.

Future Directions

At the AELRU the search for the fundamental causes of laminitis continues. Using advanced biochemical and molecular biological techniques we plan to thoroughly investigate the link between bacterial overgrowth in the horse's bowel (particularly that induced by the key pasture carbohydrate fructan) and events occurring at the basement membrane of the hoof lamellae. The real hope for horses as they confront their crippling adversary, laminitis, is a means to effectively prevent it. Once the devastating pathological cascade of laminitis is underway, the anatomical dislocations are so overwhelming that there is little hope that mankind will develop technology to be able restore a foundered foot to normal. When the reasons behind the failure of a normally robust, trouble-free attachment apparatus, between hoof and bone are understood, the way will be clear to develop effective preventive strategies.